

Original Research Article

Survival analysis pattern of patients treated with biliary metallic stent versus patients treated with surgical procedures for hepato-biliary malignancies in a rural tertiary care centre in South India

Shafique A.¹, Poppy Rejoice², Jaipaul Y.³, Ramasubramanian R.^{3*}, Heber Anandan⁴

¹Department of Medical Gastroenterology, Tirunelveli Medical College, Tirunelveli, Tamilnadu, India

²Department of Medical Gastroenterology, Kanyakumari Medical College, Asaripallam, Nagercoil, Tamilnadu, India

³Department of Medical Gastroenterology, Thoothukudi Government Medical College, Thoothukudi, Tamilnadu, India

⁴Department of Clinical Research, Dr. Agarwal's Healthcare Limited, Tamilnadu, India

Received: 10 December 2018

Accepted: 02 January 2019

*Correspondence:

Dr. Ramasubramanian R,

E-mail: ramlalli90@yahoo.com

Copyright: © the author(s), publisher and licensee Medip Academy. This is an open-access article distributed under the terms of the Creative Commons Attribution Non-Commercial License, which permits unrestricted non-commercial use, distribution, and reproduction in any medium, provided the original work is properly cited.

ABSTRACT

Background: Tumors of the biliary tract show spectrum ranging from benign to malignant lesions. Only 20% of tumors are resectable at the time of presentation. The operative mortality was approximately 5 to 20%. The morbidity rate associated with the surgery is approximately 65%. Options for palliative therapy of biliary tree obstruction include the surgical bypass, percutaneous external drainage/stenting and endoscopic stenting. The aim was to compare the survival pattern of patients treated with biliary Self Expandable Metallic Stents (SEMS) as a palliative procedure to that of patients treated by curative surgery.

Methods: This was a retrospective study. 6-months survival pattern were analysed in 20 patients treated by SEMS and compared with that of 10 patients treated with plastic biliary stents followed by curative surgery.

Results: Survival pattern analysis was done for all 20 patients with SEMS. 7 patients were in >1-year survival, 5 were in >6months survival, 6 expired within 6months, 2 patients were lost to follow up. Survival pattern was compared with 10 patients who had plastic stents followed by curative surgery. Only 1 patient had survival rate >1year post-surgery, 5 patients expired post-surgery in <6months, 2 patients expired few weeks after plastic stent deployment, 2 patients were lost to follow up.

Conclusions: In patients with biliary malignancies with obstruction, biliary SEMS followed up by palliative chemotherapy had better survival rate than patients who had plastic stents followed up with curative surgical procedures.

Keywords: Biliary tract malignancy, Biliary self-expandable metal stent, Palliative treatment

INTRODUCTION

Tumors of the biliary tract are unusual but serious problems. The spectrum of lesions ranges from benign tumors such as adenomas, to malignant lesions, such as adenocarcinomas. Despite technological advances, only 20% of periampullary tumors are found to be resectable at the time of presentation due to their invasiveness, late symptom appearance and onset in older adults.¹ Until

recently, the operative mortality rate was approximately 20%. In the past few years, several centers have reported an operative mortality rate in the range of 5%. This improvement can be attributed to increased surgical experience, improved patient selection, improved anesthesia, better preoperative imaging and general improvement in the management of ill patients.² The morbidity rate associated with the surgery is approximately 65%. In some series, 13% of patients

required a repeat laparotomy for complications. Bile duct tumors cause bile duct obstruction with biliary stasis and prolonged biliary obstruction causes hepatocellular dysfunction, progressive malnutrition, coagulopathy, pruritus, renal dysfunction, and cholangitis.³ Biliary tree obstruction and consequent jaundice occur in 70-90% of these patients and affects the patient's quality of life, morbidity and overall mortality.⁴ Options for palliative therapy of biliary tree obstruction include the surgical bypass, percutaneous external drainage/stenting and endoscopic stenting.² Hilar strictures may be caused by cholangiocarcinoma or metastatic diseases. The clinical success rates for achieving adequate palliation for hilar tumors is less than that for distal tumors.⁵ The aim was to analyze the survival pattern of patients treated with biliary Self Expandable Metallic Stents (SEMS) over a period of 2years in this centre and compared with surveillance pattern of patients treated with plastic stents followed by curative surgery.

METHODS

This retrospective study was conducted in Department of Medical Gastroenterology, Thoothukudi Government Medical College for 2years from April 2014 to March 2016 were included in the study.

Patients who were admitted to the Department of Medical Gastroenterology, Government Thoothukudi Medical College Hospital with evidence of malignant biliary tract tumours with obstructive jaundice were included in the study.

Group 1 includes the patients who were inoperable and so were treated by SEMS as palliative procedure. Inoperability status obtained from surgical oncologist obtained for all patients who were treated palliatively with SEMS placement and group 2 includes patients who were operable and who were referred for curative surgery. The patients who refused either procedures were excluded.

Age and sex pattern, liver function status, tumor marker status, imaging pattern and 6months surveillance pattern were analyzed. Similar analysis has been done for patients treated with plastic biliary stents.

RESULTS

20 patients treated with biliary metallic stent were analyzed retrospectively. 55% of patients were males, and 45% were females. 85% of the patients were above 50years of age. S. bilirubin was elevated in all the patients and was elevated >10mg% in 75% of patients. S. alkaline phosphatase was elevated in 90% of patients and more than 2-fold elevation was seen in 60% of patients (Figure 1). CA 19 9 was elevated in 90% of patients and normal in 10% of patients (Figure 2). 16 patients had periampullary growth, 2 patients had the diagnosis of hilar cholangiocarcinoma, 1 patient with HCC with CBD

invasion. 1 patient with GB carcinoma with CBD invasion. MRI abdomen with MRCP done in all 20 patients, 16 patients presented with distal biliary stricture, 4 with heterogenous mass, 1 patient has associated biliary ascariasis which was later removed. Another patient had associated pancreatic divisum.

All the patients with SEMS placement were followed with palliative chemotherapy. Survival pattern analysis was done for all 20 patients with SEMS. 7 patients were in >1-year survival pattern, 5 were in >6months survival pattern, 6 expired within 6months, 2 patients were lost to follow up. Survival pattern was compared with 10 patients who had plastic stents earlier in this department in view of follow up surgery in future. Only 1 patient had survival rate >1year post-surgery, 5 patients expired post-surgery in <6months, 2 patients expired few weeks after plastic stent deployment, 2 patients were lost to follow up (Table 1).

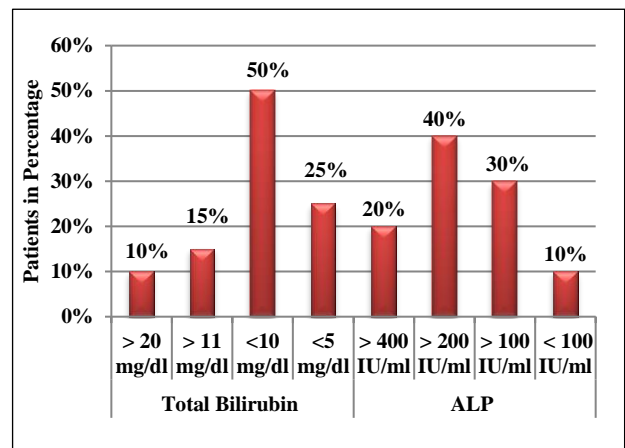


Figure 1: Total bilirubin and ALP results.

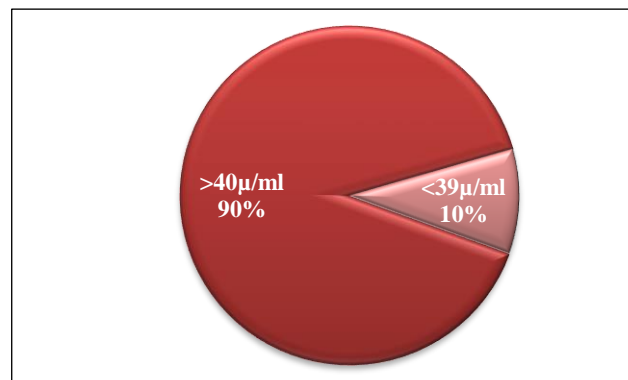


Figure 2: Distribution cancer antigen 19-9.

DISCUSSION

Malignant obstructive jaundice may be caused by pancreatic carcinoma and less commonly by ampullary cancer, primary bile duct cancer (cholangiocarcinoma), and metastatic lesions to the head of the pancreas or porta hepatis. Only 20% of tumors are found to be resectable at

the time of presentation due to their invasiveness, late symptom appearance and onset in elderly people and majority of them can only be managed palliatively.¹

Table 1: Survival pattern.

Period	Survival pattern -metallic stent (SEMS) (patients)	Survival pattern- plastic stents followed by surgery (patients)
>1-year	7	1
6months-1 year	5	5
<6months	6	6
Lost to follow up	2	2

The location of the obstruction within the biliary tree is important with regards to the palliative approach. It is divided into non-hilar and hilar biliary obstruction. It is more difficult to relieve jaundice from hilar biliary obstruction. Nonetheless, even patients with metastatic disease as the cause of hilar biliary obstruction usually can be palliated effectively using a nonsurgical approach.^{5,6}

There are three methods for palliation of obstructive jaundice which are surgical bypass, percutaneous insertion of stents, and endoscopic insertion of stents. Each of these approaches has advantages and disadvantages. There are very few comparative studies of outcomes for each of the disciplines, although nonsurgical palliation of obstructive jaundice is preferred in those with poor performance status, intra-abdominal ascites, and/or expected survival of less than 4-6months. For nonsurgical techniques, biliary stents used are composed of plastic or metal materials.

Plastic stents occlude because the formation of bacterial biofilm results in recurrent jaundice, frequently with cholangitis and necessitates stent replacement.⁷ The median time for stent occlusion for standard large-bore plastic stents is approximately 3months.

Self-expandable metal stents (SEMS) have combined the advantage of a small pre-deployment delivery system with a large post deployment stent diameter. Additionally, they are less likely to occlude than plastic stents. Metal stents still may occlude because of tumor in growth through the mesh, tumor overgrowth (tumor growing beyond the ends of the stent) or tissue hyperplasia (excessive normal tissue growth in response to the stent). SEMS may be uncovered or covered. Covered SEMS resist occlusion from tumor ingrowth or tissue hyperplasia, although they are more likely to migrate.⁸

ERCP and biliary stent placement has been shown in randomized trials to be an acceptable alternative to palliative surgical bypass.⁹ Biliary stents can be placed safely in an outpatient setting.¹⁰ In the comparative trials of surgery and endoscopy, the lower initial hospital stay

in the endoscopy group was offset by the need for subsequent hospitalization and need for subsequent ERCP to manage stent occlusion. Because the cost of expandable metal stents is much greater than that of plastic stents, they are cost-effective only if the patient lives greater than 3-6months. Metal stent occlusion generally is managed easily with placement of a plastic stent or another metal stent within the existing metal stent.¹¹ Early comparative studies have shown prolonged patency with covered metal stents compared with uncovered stents.¹²

Present study also showed that palliation with covered metallic stents in malignant biliary obstruction in patients who were unfit for curative surgical therapy was associated with prolonged survival with less morbidity and fairly good quality of life. As most of the patients presented late, they were not candidates for curative surgery. Endotherapy offers a better option compared to palliative surgery in these set of patients.

CONCLUSION

Biliary self-expanding metallic stent followed up by palliative chemotherapy had better survival rate than patients who had plastic stents followed up with surgical procedures.

Funding: No funding sources

Conflict of interest: None declared

Ethical approval: The study was approved by the Institutional Ethics Committee

REFERENCES

- Freeman ML, Sielaff TD. A modern approach to malignant hilar biliary obstruction. *Rev Gastroenterol Dis.* 2003;3(4):187-201.
- Van Laethem JL, De Broux S, Eisendrath P, Cremer M, Le Moine O, Devière J. Clinical impact of biliary drainage and jaundice resolution in patients with obstructive metastases at the hilum. *Am J Gastroenterol.* 2003;98(6):1271.
- Ballinger AB, McHugh M, Catnach SM, Alstead EM, Clark ML. Symptom relief and quality of life after stenting for malignant bile duct obstruction. *Gut.* 1994;35(4):467-70.
- Abraham NS, Barkun JS, Barkun AN. Palliation of malignant biliary obstruction: a prospective trial examining impact on quality of life. *Gastrointestinal Endoscopy.* 2002;56(6):835-41.
- Van Berkel AM, Van Marle J, Groen AK, Bruno MJ. Mechanisms of biliary stent clogging: confocal laser scanning and scanning electron microscopy. *Endoscopy.* 2005;37(08):729-34.
- Baron TH. Palliation of malignant obstructive jaundice. *Gastroenterol Clin North Am.* 2006;35(1):101-12.
- Taylor MC, McLeod RS, Langer B. Biliary stenting versus bypass surgery for the palliation of malignant

- distal bile duct obstruction: a meta-analysis. *Liver Transplantation.* 2000;6(3):302-8.
8. Cvetkovski B, Gerdes H, Kurtz RC. Outpatient therapeutic ERCP with endobiliary stent placement for malignant common bile duct obstruction. *Gastrointestinal Endoscopy.* 1999;50(1):63-6.
 9. Bueno JT, Gerdes H, Kurtz RC. Endoscopic management of occluded biliary wallstents: a cancer center experience. *Gastrointestinal Endoscopy.* 2003;58(6):879-84.
 10. Isayama H, Komatsu Y, Tsujino T, Sasahira N, Hirano K, Toda N, et al. A prospective randomised study of “covered” versus “uncovered” diamond stents for the management of distal malignant biliary obstruction. *Gut.* 2004;53(5):729-34.
 11. Cvetkovski B, Gerdes H, Kurtz RC. Outpatient therapeutic ERCP with endobiliary stent placement for malignant common bile duct obstruction. *Gastrointestinal Endoscopy.* 1999;50(1):63-6.
 12. Levy MJ, Baron TH, Gostout CJ, Petersen BT, Farnell MB. Palliation of malignant extrahepatic biliary obstruction with plastic versus expandable metal stents: an evidence-based approach. *Clin Gastroenterol Hepatol.* 2004;2(4):273-85.

Cite this article as: Shafique A, Rejoice P, Jaipaul Y, Ramasubramanian R, Anandan H. Survival analysis pattern of patients treated with biliary metallic stent versus patients treated with surgical procedures for hepato-biliary malignancies in a rural tertiary care centre in South India. *Int J Adv Med* 2019;6:146-9.