

## Original Research Article

# Detection and comparison of malaria by conventional, rapid immuno chromatographic and molecular technique

Manonmoney Jayaraman<sup>1\*</sup>, Sourav Das<sup>2</sup>

<sup>1</sup>Department of Microbiology, SRM Medical College Hospital and Research Centre, Kattankulathur, Chennai, Tamil Nadu, India

<sup>2</sup>Department of Microbiology, Mahatma Gandhi Medical College and Research Institute, SBV University, Puducherry, India

**Received:** 06 July 2020

**Accepted:** 24 July 2020

### \*Correspondence:

Dr. Manonmoney Jayaraman,  
E-mail: [drmanonmanij@gmail.com](mailto:drmanonmanij@gmail.com)

**Copyright:** © the author(s), publisher and licensee Medip Academy. This is an open-access article distributed under the terms of the Creative Commons Attribution Non-Commercial License, which permits unrestricted non-commercial use, distribution, and reproduction in any medium, provided the original work is properly cited.

## ABSTRACT

**Background:** Mosquito-borne diseases are the major concern in public health. Malaria is a protozoal disease caused by the parasites of the Genus *Plasmodium* - *Plasmodium vivax*, *Plasmodium falciparum*, *Plasmodium malariae* and *Plasmodium ovale*, which are transmitted by the bite of female *Anopheles* mosquitoes. Prevalence of malaria worldwide is about 35%. Malarial infections can be diagnosed by peripheral smear, rapid immunochromatography and molecular technique. This study is focused on *Plasmodium* species detection by using species specific primers for diagnosis. Aim and objective of this study was to detect and compare the *Plasmodium* species by conventional, rapid immunochromatographic and molecular technique in patients suspected for pyrexia of unknown origin (PUO) attending a tertiary care hospital.

**Methods:** The study was carried out at SRM MCH and RC, Tamil Nadu, India, from January 2018 to February 2019 after the institutional ethical committee approval. This was an observational study. Malarial parasites were identified in peripheral blood smear by conventional method (thick smear and thin smear), rapid immunochromatographic technique (serological technique using whole blood) and molecular technique. DNA extraction from whole blood done by spine column technique. Amplification and gel documentation done.

**Results:** Total 83 blood samples were collected from patients with clinical diagnosis of PUO. Out of 83 samples 5 (6%) samples were positive for *Plasmodium vivax* species by conventional method, rapid immunochromatographic and molecular technique.

**Conclusions:** In this study, *Plasmodium vivax* is the species identified by conventional peripheral blood smear method, rapid immunochromatographic and molecular method.

**Keywords:** Immunochromatography, Mosquito-borne, Peripheral smear, Plasmodium, Pyrexia of unknown origin, Polymerase chain reaction

## INTRODUCTION

The *Plasmodium*, well known as malarial parasites are *Sporozoans* (Class) and belong to the order Haemosporida. It is under *Phylum Apicomplexa* of subkingdom protozoa under Protista Kingdom. this *Genus Plasmodium* producing mosquito borne blood infection termed as malaria which is very common.<sup>1</sup>

Malaria is a serious, sometimes fatal life-threatening disease caused by *Plasmodium parasites* that are transmitted to people by the bites of infected female *Anopheles* mosquitoes called "malarial vectors".

Mainly four *Plasmodium* species caused infection in human. The species are *Plasmodium vivax*, *Plasmodium falciparum*, *Plasmodium malariae*, *Plasmodium ovale*.

Out of these species *P. falciparum* and *P. vivax* are the most common species and *P. falciparum* is the deadliest.<sup>2</sup>

Malaria is preventable and curable. Transmission of malaria infection depends on climatic conditions that can affect the number and existence of mosquitoes, such as rainfall patterns, temperature and moistness. Malaria is an acute state febrile illness. In an individual, clinical features appear seven days or more (may takes 10-15 days) after the bite of infective mosquito. The symptoms include various problems such as fever, headache, chills and vomiting etc. If untreated within 24 hours, *P. falciparum* malarial infection can progress to severe illness even death can also occur. Early diagnosis and treatment of malaria reduces disease rate and prevents occurrence of deaths. It also contributes to reducing malaria transmission.<sup>1</sup>

The analysis of malaria prevalence showed that there had been a tendency of declining in the total prevalence of malaria infection. Which is based on distinct seasonal summary during August, September and October. In this study it shows that the zone in Basin Bridge reflects the maximum number of malaria cases followed by Adyar zone. To understand the details of malaria prevalence in Chennai, the hotspot analysis was conducted which can give an idea that really is there any relationship existed spatially or not. It was recorded that all the wards of north eastern Chennai were malarial infection hotspots during 2005-2011. These hotspot wards bunch to form the Basin Bridge zone that was seen to be heavily malaria affected area. Another very important observation from the hotspot study analysis was that there was a sudden emergence of hotspots in southern parts of Chennai during 2011. A strong spatial relation of clustered occurrence to the prevalence of malaria in Chennai could be defined which has not previously been recorded.<sup>3</sup>

The “World Malaria Report 2017” published by World Health Organization (WHO) framed statistics from ninety-one countries and zonal areas where malaria transmission ongoing. The statistics are enriched by reports from national household inspections and databases produced by other organizations. Up to 2016 report implies that after an exceptional era of success in malaria control globally, progress has installed. It was estimated 216 million cases of malaria in 2016, an increase of about 5 million cases over 2015. A similar number of deaths reached 445,000 in contrast to the previous year.<sup>4</sup>

In Tamil Nadu, 56.6% of Malaria cases are stated from Chennai, 4.4% reported from the other urban malaria scheme towns and 39% were recorded from rural areas.<sup>5</sup>

The gold standard technique for the detection of malarial parasites in peripheral blood is thick smear and thin smear preparation and molecular diagnosis for species specific detection. In some mixed infection cases authors

can miss the other species but in molecular diagnosis we can detect all the infective species.

Polymerase chain reaction (PCR) technique is superior in amplification of the *Plasmodium spp.* 18S rRNA gene to the conventional (peripheral blood smear) and Immunochromatography rapid diagnostic test (RDT) in detecting malarial parasites. Since whole molecular setup in clinical settings is not always possible, as a result of which PCR diagnosis is currently restricted to some extent laboratory-oriented diagnosis. It serves as a useful diagnostic method for the study of epidemiological surveillance in malaria infections.<sup>6</sup>

## METHODS

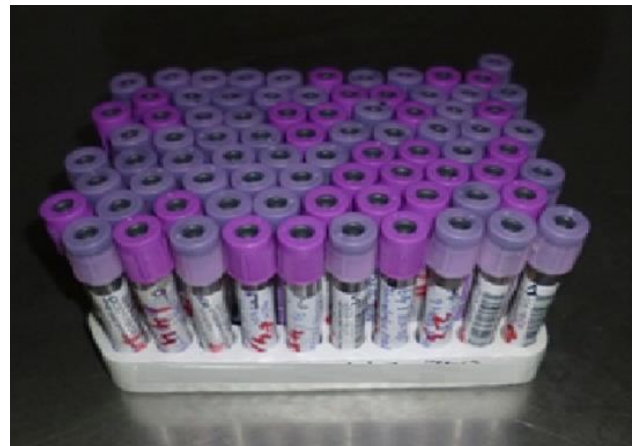
This is observational study conducted at department of microbiology, SRM Medical College Hospital and Research Centre, Kattankulathur, Chennai, Tamil Nadu, India. This was one year from January 2018 to January 2019.

This study approved by Institutional Ethical Committee of SRM, number-1288/IEC/2017.

### Specimen collection

Samples will be collected with the appropriate consent form; samples include;

- Capillary blood (peripheral blood smear preparation)
- Anticoagulated (EDTA) venous blood (molecular study).



**Figure 1: Patient samples collected in EDTA (purple top) venepuncture tube.**

Specimen collection will be followed as per as “WHO guidelines on drawing blood: best practices in phlebotomy” with appropriate aseptic precautions.

Sample taken by: Clinicians, trained nurses or phlebotomists.

Collection place: Sample collection room or specific wards, SRM MCH and RC, Kattankulathur, Chennai, Tamil Nadu, India.

Sample amount: adult: 2.5 ml; children: 1-2 ml.

### **Conventional technique peripheral blood smear preparation<sup>20-22</sup>**

#### **Preparation of thin blood film**

- A fully clean grease-free microscopic glass slide taken and a small drop of fresh blood added to the middle of the slide and a larger (about 15 mm) drop to the right side.
- The thin film prepared immediately using a slide spreader with smooth edge. Blood from anaemic patient more quickly spreading is needed with the spreader held at a vertical angle.
- Characteristics of an ideal thin smear:
  - a. Even and uniform
  - b. Consist of a single layer of RBC's
  - c. The "feathery tail end" is formed near the centre of the slide.

#### **Preparation of thick blood film**

- The large blood drop spread to prepare the thick smear without any delay. Covered uniformly an area approximately 15×15 mm. It should just be able to see (but not read) newsprint letter through the film. On the time spreading the blood, it mixed as little as possible to avoid the red cells forming marked rouleau formation which can cause the blood to be easily washed out from the slide during stain draining and washing period
- The slide was labelled by a black lead pencil with the and the patient serial number. The patients detail neatly written on the top of the thin film (after it has dried)
- The slides are allowed to dry in air in a horizontal position and placed in a slide collection box.

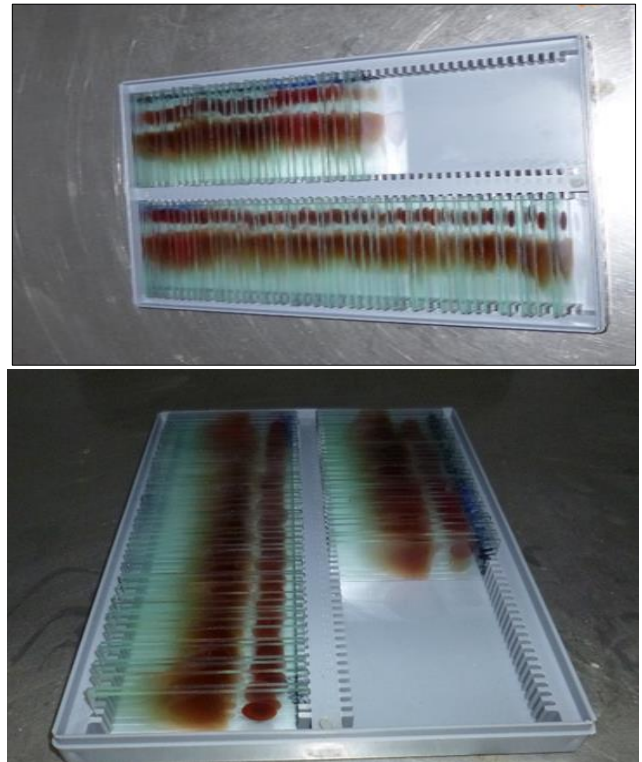
#### **Thick blood films drying**

Keep a separate box for drying malaria blood films for safe practice. Covered with a lid to protect the films from insects and dust. The box was placed in a warm place which helps to dry quickly. In humid climates, an incubator may be necessary to dry thick blood films.


#### **Method thin film fixation (slide containing a thick film)<sup>23</sup>**

- The slide placed horizontally on a level bench or on a staining rack also used
- Ethanol applied to the thin film by small drop by drop, making sure the ethanol does not touch the thick film because it will prevent the lysis of the red blood cells and make the thick film unobservable. Alternatively, the methanol can be applied to the thin

film using a swab. Allow the thin film to fix for 1-2 minutes (Figure 3).



**Figure 2: Prepared methanol fixed peripheral blood smear and preservation.**




**Figure 3: Dehaemoglobinization process by using distilled water.**

#### **Dehaemoglobinization<sup>22</sup>**

##### **Tartaric acid and glacial acetic acid with tartaric acid mixture method**

The film is flooded with the mixture and as soon as dehaemoglobinization is completed (the grayish-white colour of the film is the indication), by tilting the fluid is drained off. The smear fixed with methyl alcohol for 3 to 5 minutes. Then the slide was washed thoroughly with

neutral distilled water or slightly alkaline distilled water so that every traces of acid neutralized and removed.



**Figure 4: Glass slide of thick smear before and after dehaemoglobinization.**

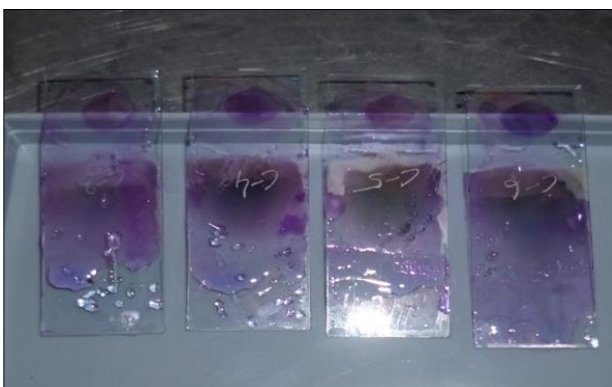In distilled water the film placed in vertical position in a coplin jar for 5 to 10 minutes. When the film becomes colourless or faint, then taken out and allowed to dry in air in an upright position (Figure 4).

#### Staining procedure<sup>23</sup>

Thin blood smear (only smear not the whole slide) is flooded with 5-10 drops of stain. After 2 minutes, the stain is diluted by adding twice as many drops of buffered distilled water. This solution is allowed to mix with the help of a pasture pipette.

This solution is allowed for 15-20 minutes for staining.

The slide is washed with buffered distilled water, rinsed dry, and examined under the microscope (Figure 5).



**Figure 5: Glass slides of thick and thin smear stained by Leishman stain.**

#### Observation<sup>24-26</sup>

Different characters of erythrocytic phases, malarial pigments and various types of dots (Schuffner's dots,

Maurer's dots.) of infected RBCs are observed under microscope and species detection (Figure 6-11).

#### *Plasmodium falciparum*

This species is potentially the most dangerous and infections should be diagnosed as early as possible. In the peripheral blood smear, look for the following:

- The infected erythrocytes are normocytic compared to uninfected erythrocytes.
- Tiny ring forms occupy less than 1/3 the of the erythrocyte diameter.
- Often, various forms are seen in one erythrocyte.
- Often, two nuclei can be seen in the same ring.
- Infections can be heavy, involving near 20% or more of the erythrocytes, indicating a fulminant infection (i.e., hyper parasitemia).
- The tiny rings often are plastered on the erythrocyte cell membrane, known as an "appliqué" form.
- Advanced forms (i.e., amoeboid trophozoites and Schizonts) are rarely seen in stained thin blood smears. Only forms usually seen are early ring forms and gametocytes.
- The existence of banana or crescent-shaped gametocytes is diagnostic key. These may be absent in early stages of infection and usually begin to appear only after 8 to 10 days after onset of temperature rise. Therefore, it is imperative that the parasitologist be able to identify *P. falciparum* in the absence of these forms.

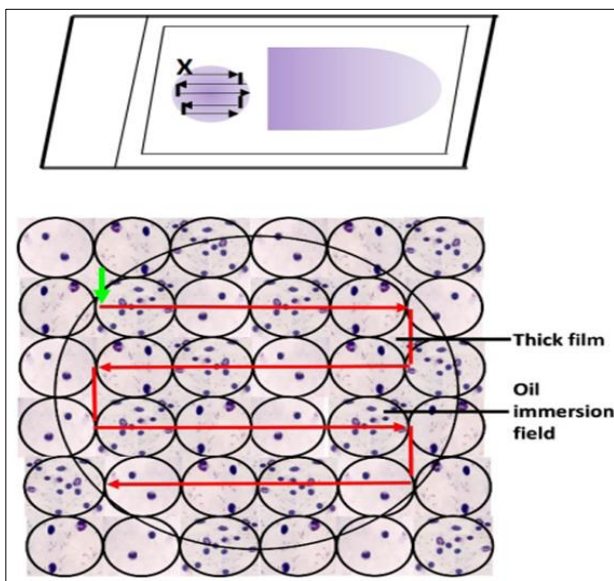
#### *Plasmodium vivax*

Look for the following features in the peripheral smear:

- Infected erythrocytes that are macrocytic compared with uninfected erythrocytes.
- The infected erythrocytes may contain small, regular, punctate pink-red-staining granules in the erythrocyte membranes, called Schuffner's dots.
- These dots are dependent on the pH of the stain and are not always present. The Wright's stain used in hematology, for example, is not pH balanced, and so Schaffner's dots will not be present. It should also be noted that *P. falciparum* very rarely contains larger, "comma-shaped" red dots called Maurer's clefts, so the presence of dots should not be the sole criteria for identification. It must be used in conjunction with the other morphology features present.
- Ring forms in all stages of development may be present.
- Young rings measure greater than 1/3 of the infected erythrocyte diameter.
- As the trophozoites mature, they transform from the ring trophozoites into the amoeboid trophozoites.
- Amoeboid trophozoites undergo consecutive rounds of mitosis to form a cluster of merozoites called a

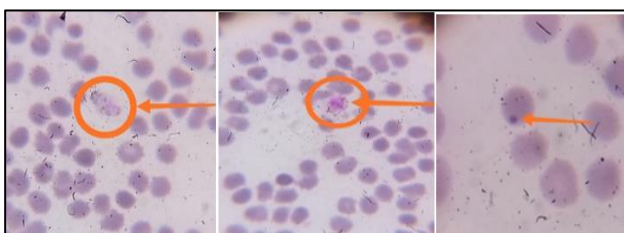Schizonts. The Schizonts of *P. vivax* consist of 12 to 13 or more merozoites.

- Gametocytes presence as large and circular. Any single-celled nucleus occupying the majority of the cell diameter is likely a gametocyte.
- Amoeboid trophozoites can always be distinguished from gametocytes, because by the time an amoeboid trophozoites reaches the size of half the diameter of the cell, it will undergo cellular division to form the Schizonts. Conversely, the gametocyte will continue to grow, occupying more than half of the cytoplasm, yet still remaining one nucleus; abundant hemozoin pigment is also often present.
- Malarial pigment in finely granular form, brownish pigment may be more in both the schizonts and the gametocyte.



**Figure 6: Examination procedure for a thick blood film.**

Source: malaria microscopy standard operating procedure-MM-SOP-08, WHO.



**Figure 7: (A) Thin smear of plasmodium vivax, (B) late trophozoite, (C) early trophozoite**

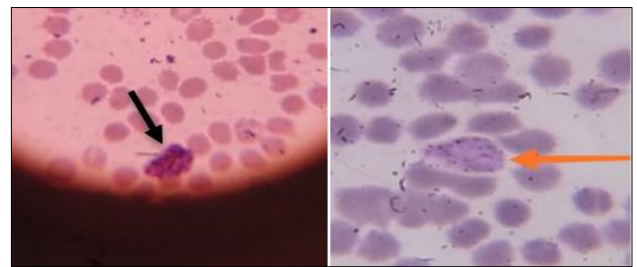
*P. malariae*

- Infected erythrocytes are normocytic compared with uninfected erythrocytes.
- The presence of amoeboid trophozoites that form a “Band” across the infected erythrocytes.

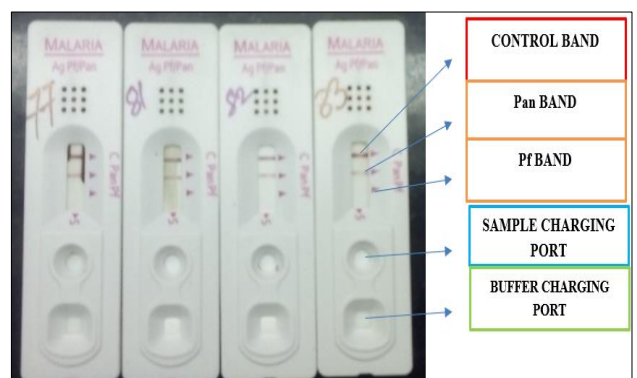
- There are no “dots” (e.g., Schaffner’s Dots) ever present.
- Schizonts consist of 6 to 12 merozoites, which often form a “Rosette”.
- Gametocytes are round and contained within normal-sized erythrocytes.

*P. ovale*

- The infected erythrocytes are macrocytic compared with the uninfected erythrocytes.
- Infected cells that are oval and have a fimbriated edge may be seen.
- The amoeboid trophozoites is more compact than that of *P. vivax*, usually occupying only one-third of the cytoplasm of the infected cell.
- James’ stippling, which are dots indistinguishable from Schaffner’s dots, may be seen, but are also pH dependent.
- Schizonts contain 6 to 12 merozoites.
- The gametocytes are round, rather than crescent-shaped, which does not help differentiate them from *P. vivax* and *P. malariae*, but does differentiate them from *P. falciparum*.



**Figure 8 (A and B): Thin smear of Plasmodium vivax (A) mature schizonts, (B) female gametocytes.**



**Figure 9: Rapid diagnostic tests positive for plasmodium vivax and negative for plasmodium falciparum.**

**Immunochromatographic technique**

Several malarial antigens can be detected in ICT

**Parasitic lactate dehydrogenase (pLDH)**

It is produced by trophozoites and gametocytes of all Plasmodium species. Currently, available test kits can differentiate panmalarial pLDH common to all species and pLDH specific to *P. falciparum*.

**Parasitic aldolase**

It is produced by all Plasmodium species. *P. falciparum*-specific histidine-rich protein 2 (PfHRP-2): It is produced by trophozoites and young (but not mature) gametocytes of *P. falciparum*.

Most of the kits are designed to detect a combination of two antigens. One is *P. falciparum*-specific antigen HRP-2 or pLDH specific for *P. falciparum*. Other is a

panmalarial antigen like aldolase or panmalarial pLDH.<sup>27,28</sup>

**Interpretation**

*In positive cases*

The labelled antigen antibody complexes will be immobilized at the corresponding pre deposited lines coated with capture antibody specific for *P. falciparum*, pan malarial capture antibody.

*In both positive and negative cases*

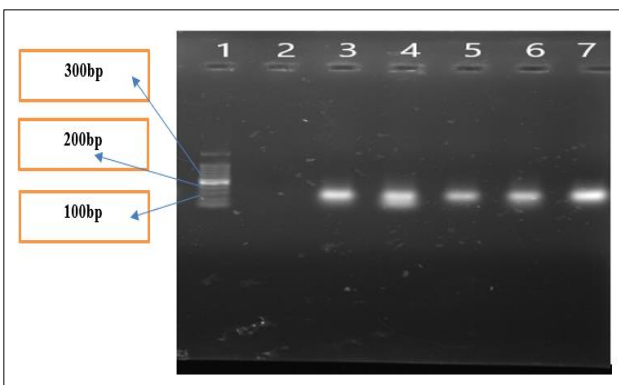
The control band is formed due to binding of the labelled polyclonal malarial antibody to the control antibody. Absence of the control band indicates the test is invalid.

**Table 1: The primer sequence for specific plasmodium species.**

Species	Primer	Sequence (5'-3')	Size (bp)
<i>P. falciparum</i>	FAL (F)	TTAAACTGGTTTGGGAAAACCAAATATATT	205
	FAL (R)	ACACAATGAACTCAATCATGACTACCCGTC	
<i>P. vivax</i>	VIV (F)	CGCTTCTAGCTTAATCCACATAACTGATAC	120
	VIV (R)	ACTTCCAAGCCGAAGCAAAGAAAGTCCTTA	
<i>P. ovale</i>	OVA (F)	ATCTCTTTTGCTATTTTTTAGTATTGGAGA	800
	OVA (R)	GGAAAAGGACACATTAATTGTATCCTAGTG	
<i>P. malariae</i>	MAL (F)	ATAACATAGTTGTACGTTAAGAATAACCGC	144
	MAL (R)	AAAATTCCCATGCATAAAAAATTATACAAA	

**Table 2: PCR program timing schedule.<sup>34</sup>**

PCR program			
Steps	Temp (°C)	Time (min)	No. of cycles
Denaturation	94	1	30
Annealing	58	2	30
Elongation	72	2	30



**Figure 10: Gel documentation lane 1: DNA ladder (1000 bp), lane 2: negative control, lane 3 to lane 7 shows plasmodium vivax gene (120 bp).**

**Molecular technique**

*Polymerase chain reaction (PCR)*

DNA extraction: *Plasmodium* DNA will be extracted by a standardized procedure from the intact RBCs by using saponin solution based on HELINI Pure fast human blood DNA Minispin Prep Kit (Cat. No.: 2003-25/50/100 Purifications). DNA will extract from 200 µl of thawed EDTA-blood according to the manufacturer’s instructions.

*PCR amplification<sup>34</sup>*

After amplification the products can be kept at 4°C overnight or frozen at (-20°C) for long-term storage.<sup>35</sup>

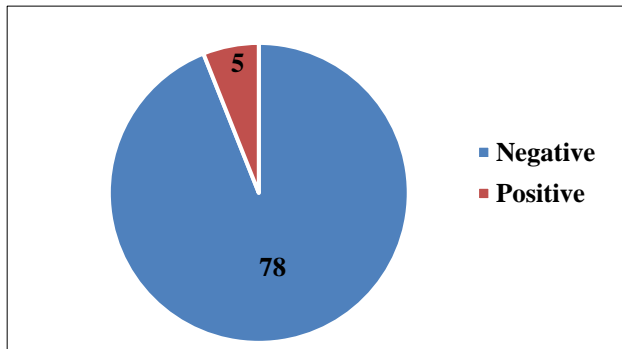
DNA amplification using recommended PCR program.

*Gel documentation*

- For analysis of the PCR data, Agarose gel electrophoresis done.
- 100 Kb DNA ladder in separate well as a positive control.

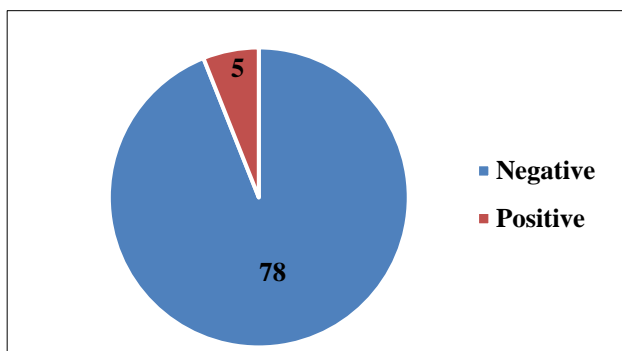
**RESULTS**

The study on “detection and comparison of malaria by conventional, rapid immuno chromatographic and molecular technique” is a hospital based prospective study done in SRM Medical College Hospital and Research Centre with a total of 83 clinically suspected PUO patients during the period of January 2018 to February 2019. Out of 83 samples, 5(6%) samples were positive for *Plasmodium vivax* species by conventional method, rapid immunochromatographic and molecular technique with similar sensitivity and specificity.



**Figure 11: Number of positive cases diagnosed by peripheral blood smear (n=83).**

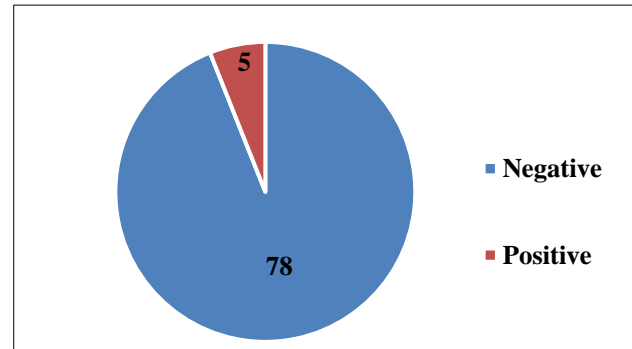
Figure 11 shows number of positive cases by peripheral blood smear, n=83, malarial parasite positive: 5, malarial parasite negative: 78.



**Figure 12: Number of positive cases diagnosed by immunochromatographic method in blood (n=83).**

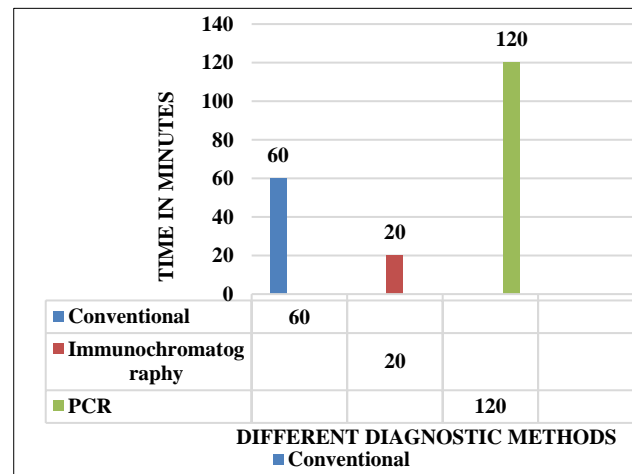
Figure 12 shows number of positive cases detected by immuno chromatography, n=83, malarial antigen positive: 5, malarial antigen negative: 78.

Figure 13: number of positive cases detected by PCR n=83, positive for *plasmodium vivax* gene-5, negative for *Plasmodium* species -78.



**Figure 13: Number of positive cases diagnosed by PCR in blood (n=83).**

Figure 14, explains the turnaround time in different diagnostic methods namely conventional peripheral smear, rapid diagnostic tests and PCR used in detecting malarial parasitic infections.



**Figure 14: Comparison of turnaround time (TAT) between three different diagnostic methods.**

**DISCUSSION**

The present study on the “detection and comparison of malaria by conventional, rapid immuno chromatographic and molecular technique” a hospital based prospective study done in SRM Medical College Hospital and Research Centre 83 patients during the period of January 2018 to February 2019.

In 2017, there were an estimated 4,35,000 deaths from malaria globally stated by WHO. So early and specific diagnosis is very much needed to reduce mortality and morbidity rate.<sup>4</sup>

In this study prevalence rate of Plasmodium infection in Kattankulathur region is 6% which is an increased

percentage in contrast with the report of NVDCP and State Health Society Tamil Nadu, National Health Mission where they reported the prevalence in urban malaria areas was 4.4%.<sup>5</sup>

Murawala S et al studied that the most common type of malaria parasite was *P. vivax* in the younger age group. This statement supports this study where out of 83 patients' sample 5 samples were positive for *Plasmodium vivax*.<sup>2</sup>

Siwal N et al the proportion was found to be 49:51 *Plasmodium falciparum* and *Plasmodium vivax* respectively. Mixed species infections also found in 13% cases of total infections due to *Plasmodium falciparum* and *Plasmodium vivax*. In this study *Plasmodium vivax* only identified and confirmed by the appearance of erythrocytic stage by conventional method and confirmed by PCR method. Mixed infections were not seen in this study as confirmed by PCR. As a justification of this study is that, Siwal N et al, studied on 2,333 samples from malaria endemic regions in various geographic location in India whereas in this study, sample size is 83 which is very less in contrast with the other study.<sup>6</sup>

## CONCLUSION

In this study, *Plasmodium vivax* is the most common species identified by conventional method and rapid immunochromatography method (ICT) showing same sensitivity and specificity.

Conventional technique is a gold standard technique but also time-consuming process and expert microbiologist or pathologist is needed for reporting. The rapid Immunochromatographic test can be done very easily comparatively less time and also sensitive and specific.

Molecular technique is specific for species differentiation but its more time consuming and complex procedure. Molecular setup for urban area laboratory is difficult and expensive as a daily routine work.

*Funding: No funding sources*

*Conflict of interest: None declared*

*Ethical approval: The study was approved by the Institutional Ethics Committee of SRM (1288/IEC/2017)*

## REFERENCES

1. Parija SC, Textbook of medical parasitology protozoology and helminthology text and colour atlas. 4<sup>th</sup> edition. New Delhi. All India Publishers and Distributors; 2016.
2. Murawala SM, Chudasama V, Vegad M. Prevalence of mosquito-borne plasmodium infection in patients attending fever clinic in a tertiary-care teaching hospital, western India. Int J Med Sci Public Health. 2015;4(11):1598-602.
3. Kumar DS, Andimuthu R, Rajan R, Venkatesan MS. Spatial trend, environmental and socioeconomic

factors associated with malaria prevalence in Chennai. Malaria J. 2014;13(1):1-9.

4. The world Malaria Report 2017. World Health Organization 2017. Available at: <https://www.who.int/malaria/publications/world-malaria-report-2017/report/en/>. Accessed on 13th May 2020.
5. National Health Mission. Vector borne disease control programme. Available at: <http://www.nrhmtn.gov.in/vbdc.html>
6. Siwal N, Singh US, Dash M, Kar S, Rani S, Rawal C, et al. Malaria diagnosis by PCR revealed differential distribution of mono and mixed species infections by Plasmodium falciparum and P. vivax in India. PLoS One. 2018;13(3):e0193046.
7. Kumar DS, Andimuthu R, Rajan R, Venkatesan MS. Spatial trend, environmental and socioeconomic factors associated with malaria prevalence in Chennai. Malaria J. 2014;13(1):1-9.
8. Murawala SM, Chudasama V, Vegad M. Prevalence of mosquito-borne plasmodium infection in patients attending fever clinic in a tertiary-care teaching hospital, western India. Int J Med Sci Public Health. 2015;4(11):1598-602.
9. Siwal N, Singh US, Dash M, Kar S, Rani S, Rawal C, et al. Malaria diagnosis by PCR revealed differential distribution of mono and mixed species infections by Plasmodium falciparum and P. vivax in India. PLoS One. 2018;13(3):e0193046.
10. Jenkins R, Omollo R, Ongecha M, Sifuna P, Othieno C, Ongeri L, et al. Prevalence of malaria parasites in adults and its determinants in malaria endemic area of Kisumu County, Kenya. Malaria J. 2015;14(1):263.
11. de Oliveira AM, Mutemba R, Morgan J, Streat E, Roberts J, Menon M, et al. Prevalence of malaria among patients attending public health facilities in Maputo City, Mozambique. The Am J Trop Med Hygiene. 2011;85(6):1002-7.
12. Pathania S, Goel N. Advance techniques for diagnosis of malaria: a review. Int J Applied Res. 2017;3(11):210-2.
13. Vora BA, Bindu RS. Comparison of diagnostic methods of malaria by peripheral smear, centrifuged buffy coat smear and rapid antigen detection test. Int J Res Med Sci. 2017;5(10):4532-7.
14. Shah LP, Krishnamoorthy N, Vijayakumar T, Basker P. Risk of malaria transmission in stone quarry sites of Villupuram district in Tamil Nadu, India. Int J Mosquito Res. 2018;5(1):33-40.
15. Vishalakshi B, Mariraj J, Liba S, Krishna S. Cross sectional study comparing peripheral blood smear and rapid antigen detection test in diagnosis of malaria conducted during monsoon and post monsoon period at Ballari, India. Int J Curr Microbiol Applied Sci. 2018;7(2):255-60.
16. Kim JY, Ji SY, Goo YK, Na BK, Pyo HJ, Lee HN, et al. Comparison of rapid diagnostic tests for the detection of Plasmodium vivax malaria in South Korea. PLoS One. 2013;8(5):e64353.
17. Krishna S, Bharti PK, Chandel HS, Ahmad A, Kumar R, Singh PP, et al. Detection of mixed infections with Plasmodium spp. by PCR, India, 2014. Emerging Infect Dis. 2015;21(10):1853.



18. Lauderdale JM, Caminade C, Heath AE, Jones AE, MacLeod DA, Gouda KC, et al. Towards seasonal forecasting of malaria in India. *Malaria J.* 2014;13:310.
19. WHO guidelines on drawing blood: best practices in phlebotomy, WHO Library Cataloguing-in-Publication Data, ISBN 9789241599221, World Health Organization, 2010. Available at: <https://apps.who.int/iris/handle/10665/44294>. Accessed on 13<sup>th</sup> May 2020.
20. Monica Cheesbrough. *District Laboratory Practice in Tropical Countries.* 2<sup>nd</sup> Edition. Part 1. Page. 246 New York. CAMBRIDGE UNIVERSITY PRESS, 2009. Available at: <https://medicallabtechno.weebly.com/uploads/7/5/1/5/7/515789/monica-cheesbrough-district-laboratory-practice-in-tropical-countries-part-1.pdf>. Accessed on 15<sup>th</sup> May 2020.
21. Chatterjee KD, Parasitology, Protozoology and Helminthology, Thirteenth Edition, CBS Publication; 2009.
22. Malaria microscopy standard operating procedure - mm sop-06b, recording and reporting microscopy results, version 1 - effective, 2016. World health organization. Available at: <https://apps.who.int/iris/bitstream/handle/10665/274382/MM-SOP-06b-eng.pdf?sequence=10&isAllowed=y>. Accessed on 15<sup>th</sup> May 2020.
23. WHO. National malaria slide bank standard operating procedures. Geneva. Available at: <http://www.pbhealth.gov.in/SOP-Quality-Assurance-Microscopy.pdf>. Accessed on 17<sup>th</sup> May 2020.
24. Procop GW, Church L, Hall GS, Janda WM, Koneman EW, Schreckenberger PC, Koneman's Color Atlas and Textbook of Diagnostic Microbiology, 7<sup>th</sup> Edition; Wolters Kluwer. China; 2017.
25. Krishna S, Bharti PK, Chandel HS, Ahmad A, Kumar R, Singh PP, et al. Detection of mixed infections with *Plasmodium* spp. by PCR, India, 2014. *Emerging Infect Dis.* 2015;21(10):1853.
26. WHO. Basic malaria microscopy. Part I. Learner's guide. Second edition. Geneva: 2010
27. Ifeorah IK, Brown BJ, Sodeinde OO. A comparison of rapid diagnostic testing (by *Plasmodium* lactate dehydrogenase), and quantitative buffy coat technique in malaria diagnosis in children. *African J Infect Dis.* 2017;11(2):31-8.
28. Treatment of Malaria (Guidelines for Clinicians), 2013. Available at: <https://www.cdc.gov/malaria/resources/pdf/clinicalguidance.pdf>. Accessed on 14<sup>th</sup> May 2020.
29. Gomes LT, Tada MS, Katsuragawa TH, Póvoa MM, Viana GM, Maria das Gracas CA, et al. Low sensitivity of malaria rapid diagnostic tests stored at room temperature in the Brazilian Amazon Region. *The J Infect Develop Countries.* 2013;7(3):243-52.
30. Thomas S, Ravishankaran S, Justin NJ, Asokan A, Mathai MT, Valecha N, et al. Resting and feeding preferences of *Anopheles stephensi* in an urban setting, perennial for malaria. *Malaria J.* 2017;16(1):1-7.
31. Subudhi AK, Boopathi PA, Middha S, Acharya J, Rao SN, Mugasimangalam RC, et al. A cross strain *Plasmodium falciparum* microarray optimized for the transcriptome analysis of *Plasmodium falciparum* patient derived isolates. *Genomics Data.* 2016;9:118-25.
32. Dinko B, Oguike MC, Larbi JA, Bousema T, Sutherland CJ. Persistent detection of *Plasmodium falciparum*, *P. malariae*, *P. ovale curtisi* and *P. ovale wallikeri* after ACT treatment of asymptomatic Ghanaian school-children. *Int J Parasitol Drugs and Drug Resist.* 2013;3:45-50.
33. Anthony C, Lau MR, Syedomar SF, Ponnampalavanar SRS. Comparison of two nested PCR methods for the detection of human malaria. *Tropical Biomed.* 2013;30(3):459-66.
34. Kumar DS, Andimuthu R, Rajan R, Venkatesan MS. Spatial trend, environmental and socioeconomic factors associated with malaria prevalence in Chennai. *Malaria J.* 2014;13(1):1-9. Available at: <http://www.malariajournal.com/content/13/1/14>
35. Antony HA, Das S, Parija SC, Padhi S. Sequence analysis of *pfprt* and *pfmdr1* genes and its association with chloroquine resistance in Southeast Indian *Plasmodium falciparum* isolates. *Genomics Data.* 2016 Jun 1;8:85-90..
36. Miguel-Oteo M, Jiram AI, Ta-Tang TH, Lanza M, Hisam S, Rubio JM. Nested multiplex PCR for identification and detection of human *Plasmodium* species including *Plasmodium knowlesi*. *Asian Pacific J Trop Med.* 2017;10(3):299-304.
37. Noedl H, Yingyuen K, Laoboonchai A, Fukuda M, Sirichaisinthop J, Miller RS. Sensitivity and specificity of an antigen detection ELISA for malaria diagnosis. *The Am J Trop Med Hygiene.* 2006;75(6):1205-8.
38. de Oca MM, Kumar R, de Labastida Rivera F, Amante FH, Sheel M, Faleiro RJ, et al. Type I interferons regulate immune responses in humans with blood-stage *Plasmodium falciparum* infection. *Cell Reports.* 2016;17(2):399-412.
39. Gama BE, do ES Silva-Pires F, Lopes MN, Cardoso MA, Britto C, Torres KL, et al. Real-time PCR versus conventional PCR for malaria parasite detection in low-grade parasitemia. *Experimental Parasitol.* 2007;116(4):427-32.

**Cite this article as:** Jayaraman M, Das S. Detection and comparison of malaria by conventional, rapid immuno chromatographic and molecular technique. *Int J Adv Med* 2020;7:1400-8.