

Case Report

A case of juvenile polymyositis post viral hepatitis A

Hanock Unni Samuel*, N. V. Jayachandran, N. K. Thulaseedharan

Department of Medicine, Government Medical College, Calicut, Kerala, India

Received: 23 February 2017

Accepted: 28 March 2017

*Correspondence:

Dr. Hanock Unni Samuel,

E-mail: hanockunnisamuel@gmail.com

Copyright: © the author(s), publisher and licensee Medip Academy. This is an open-access article distributed under the terms of the Creative Commons Attribution Non-Commercial License, which permits unrestricted non-commercial use, distribution, and reproduction in any medium, provided the original work is properly cited.

ABSTRACT

Polymyositis is rare as a stand-alone entity and is often misdiagnosed; most patients whose condition has been diagnosed as polymyositis have inclusion-body myositis, necrotizing autoimmune myositis, or inflammatory dystrophy. Polymyositis remains a diagnosis of exclusion and is best defined as a subacute proximal myopathy in adults who do not have rash, a family history of neuromuscular disease, exposure to myotoxic drugs (e.g. statins, penicillamine, and zidovudine), involvement of facial and extraocular muscles, endocrinopathy, or the clinical phenotype of inclusion body myositis. The etiology of polymyositis may be due to underlying systemic autoimmune diseases, viral, parasitic, bacterial infections or drug induced. Here we describe a case of juvenile polymyositis post viral infection with hepatitis A.

Keywords: Juvenile polymyositis, Post viral, Viral hepatitis A

INTRODUCTION

Polymyositis is rare as a stand-alone entity and is often misdiagnosed; most patients whose condition has been diagnosed as polymyositis have inclusion-body myositis, necrotizing autoimmune myositis, or inflammatory dystrophy. Polymyositis remains a diagnosis of exclusion and is best defined as a subacute proximal myopathy in adults who do not have rash, a family history of neuromuscular disease, exposure to myotoxic drugs (e.g. statins, penicillamine, and zidovudine), involvement of facial and extraocular muscles, endocrinopathy, or the clinical phenotype of inclusion body myositis.¹ The etiology of polymyositis may be due to underlying systemic autoimmune diseases, viral, parasitic, bacterial infections or drug induced. Here we describe a case of juvenile polymyositis post viral infection with hepatitis A.

CASE REPORT

A 14-year-old female, 9th standard student presented with complaints of myalgia, generalised edema and puffiness of muscles and difficulty in getting up from squatting

position of 1½ months duration. Her complaints started as myalgia initially in both thigh and arms, later the muscle pain became generalised and was associated with generalised edema and puffiness of all muscles; she also had difficulty in climbing upstairs, getting up from squatting position, difficulty in combing hair and lifting her arms overhead. There was also difficulty in lifting neck and rolling over in bed, there is history of one episode of nasal regurgitation. She also had fever for past 3 days.

Her past history revealed that she was apparently normal 2½ months back when there was a history suggestive of viral hepatitis in her family with clustering of cases. She herself experienced fever and increased fatigue for which she sought medical attention and was found to have elevated ALT, her IgM HAV was reactive at that time (8.35 over a cutoff of 1.0). She was started on oral medications and improved symptomatically. There was no history of any sensory symptoms, no history of any skin rash, no history of breathlessness, ptosis, diplopia; no history of decreased urine output or cola coloured urine, no diurnal variation of symptoms, no history of any oral ulcers, arthralgia, excessive hair loss, constipation or

cold intolerance. She was not on any regular medications; she was the 4th child born out of a non- consanguineous marriage. There was no family history of similar illness. She had normal menstrual cycles and had good scholastic performance being the top performer in her school.

The possibilities considered from history were that of inflammatory myopathies, endocrinopathies, muscular dystrophy or metabolic myopathies with a background history of viral hepatitis A. With this we proceeded on to examination. She was lying comfortably in bed during examination, moderately built and nourished with a BMI of 19.5kg/m². There was no pallor, icterus, cyanosis, clubbing, lymphadenopathy, generalised edema and muscle stiffness was noted, muscle tenderness was also present. There were no skin rashes; her breast and thyroid were normal. On systemic examination of nervous system showed that her higher mental functions were normal. There was no evidence of any cranial nerve involvement, her fundus was normal bilaterally; motor system examination showed generalised puffiness of muscles, muscle tone was decreased in all four limbs, muscle power was grade 4/5 in proximal muscles of all muscle groups in bilateral upper and lower limbs and was normal grade 5/5 distally. There was difficulty in holding up her head, all the deep tendon reflexes were sluggish and knee jerk was absent. Plantar response was bilateral flexor and she had a waddling type of gait. There were no involuntary movements. Her sensory system examination was normal and there were no signs of any autonomic dysfunction. Skull and spine was also normal. Other systems on examination- cardiovascular system- S1S2 normal, no murmurs, no added sounds. Respiratory system- bilateral normovesicular breath sounds of equal intensity, gastrointestinal system-normal, no hepatosplenomegaly.

So, we had a patient with myalgia, muscle tenderness, proximal muscle weakness of bilateral upper and lower limbs, neck muscle weakness, which was an LMN syndrome, so the differential diagnosis considered at this point of time were Inflammatory myopathy-polymyositis; endocrinopathies-hypothyroidism. The possibility of polymyositis was considered first as there was no cutaneous lesions and due to an association with post viral infection with hepatitis A.

Hence proceeded onto the investigations which showed an elevated total count of 18,500 which was neutrophil predominant- N84.2% L9.2% M6.6%. Her haemoglobin was 11.8g/dl, with a hematocrit of 36.2%; MCV was 92.8fl and a Platelet count of -3.47 lakhs/cumm; ESR was 30mm in the first hour. Random blood sugar of 114mg/dl. Blood urea/serum creatinine of 33/0.8, sodium/potassium of 134/4.1, serum total bilirubin/conjugated bilirubin of 0.6/0.2, serum total protein/albumin of 5.6/3.1, alanine amino transferases/alkaline phosphatase of 88/83, prothrombin time /INR-15.2/1.06. Serum calcium was 8.7 mg/dl; serum phosphorous 4.2 mg/dl, serum uric acid level of

7.0 mg/dl and serum magnesium of 1.4mg/dl. Her urine routine showed Albumin trace, sugar-nil, 1-2 Epithelial cells/High power field, C Reactive protein was 135.75 (0-6), HIV/HBsAg/HCV was negative. Her chest X-ray was within normal limits, electrocardiogram was showed normal sinus rhythm, ultrasound of abdomen was within normal limits. Her thyroid function tests showed FT4-1.2 (0.61-1.12), TSH-0.92 (0.34-5.6), Anti-TPO-13.58IU/ml (0-34) ruling out any thyroid myopathy. Her creatinine kinase levels showed:

Table 1: Creatinine levels on different days.

Date	CPK
12-11-16	8581.4 U/L
15-11-16	5743.5 U/L
17-11-16	3078.8 U/L
21-11-16	5830 U/L
29-11-16	412 U/L

Lactate dehydrogenase levels were 719U/L (140-280), aspartate aminotransferases 353U/L, alanine aminotransferase was 116U/L; urine myoglobin was negative.

To rule out eosinophilic myositis an absolute eosinophil count was done which was 350 (30-350). Total IgE was 690.6U/ml (150-300) and peripheral smear was normal without any evidence of eosinophilia, hence ruling out eosinophilic myositis. An ANA profile was done to rule out any autoimmune myopathies and was negative; anti ds DNA and anti Jo 1 were negative. An electromyogram was done which showed low amplitude, short duration, occasionally polyphasic motor unit potentials noted in left tibialis anterior and right quadriceps which was suggestive of a myopathic pattern.

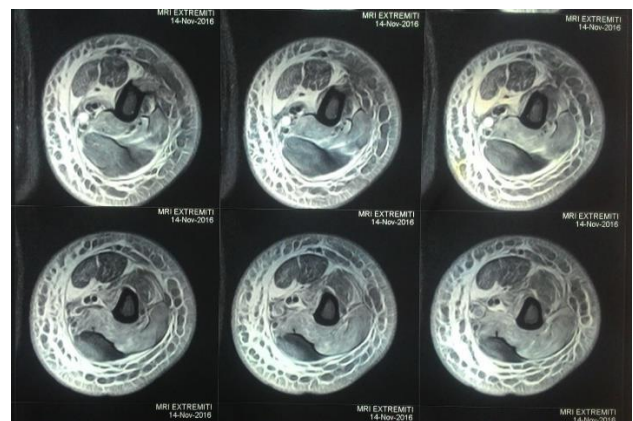


Figure 1: MRI of left upper arm.

An MRI of left upper arm showed diffuse muscle atrophy with intramuscular, intermuscular and subcutaneous edema in left upper limb, predominantly affecting the triceps, coracobrachialis and relatively sparing the biceps and long head of triceps.

A muscle biopsy was done from the biceps muscle which did not show any significant inflammation. An ECHO scan was done to rule out any cardiac involvement and was normal. Hence after the workup the final diagnosis of polymyositis was made.

DISCUSSION

Polymyositis is an inflammatory muscle disease that may be closely related to immune-mediated processes triggered by exposure to environmental factors in genetically susceptible individuals. The triggering event of myositis is unknown, but infectious agents including bacteria, viruses, and parasites have been implicated. Among these agents, a variety of viral infections associated with myositis have been reported.² Influenza virus, echovirus, and adenovirus have been cultured in some patients with myositis. Electron microscopy analysis

has also identified enterovirus (coxsackie virus) in some patients with PM. Retroviruses, including HIV and human T-cell leukaemia-lymphoma virus type I, have been associated with the inflammatory myopathies on the basis of clinical and histopathologic findings. Polymyositis is a rare extrahepatic manifestation of viral hepatitis A. Various mechanisms have been proposed for virus-induced myositis, such as direct injury to muscle, alteration of muscle function from nearby infection, and an autoimmune response to viral antigens bound to intracellular enzymes.

The criteria for diagnosis of polymyositis and dermatomyositis was proposed by Bohan and Peter.³ First rule out all other forms of myopathy. Symmetrical weakness, usually progressive, of the limb-girdle muscles, muscle biopsy evidence of myositis-necrosis of type I and type II muscle fibres, phagocytosis, degeneration and regeneration of myofibres with variation in myofibre size, endomysial, perimysial, perivascular or interstitial mononuclear cells.⁴ Elevation of serum levels of muscle-associated enzymes CK, aldolase, LD, transaminases (ALT/SGPT and AST/SGOT), electromyographic triad of myopathy-short, small, low-amplitude polyphasic motor unit potentials, fibrillation potentials, even at rest, bizarre high-frequency repetitive discharges and characteristic rashes of dermatomyositis

Definite PM defined as all first four elements, probable PM as three of first four and possible PM as two of first four; definite DM defined as rash plus three other elements, probable DM as rash plus two others and possible DM as rash plus one other. Consequently, the following nine features were proposed as criteria for PM/DM: Heliotrope rash, Gottron's sign or linear extensor erythema; proximal weakness of the upper or

lower extremity and trunk, elevation of CK or aldolase levels, muscle pain on grasping or spontaneous muscle pain, the EMG triad of myopathy, presence of anti-Jo-1 autoantibodies, non-destructive arthritis or arthralgias, signs of systemic inflammation (fever >37°C at the axilla, elevated C-reactive protein or erythrocyte sedimentation rate) and muscle biopsy evidence of myositis (inflammatory infiltrate with degeneration or necrosis of muscle, active phagocytosis, central nuclei or active regeneration).

With these criteria, definite PM was defined as any four of the nine features without rash, with a sensitivity of 99% and a specificity against all other diseases of 95%.⁵

In present case, the etiology had to be determined so an IgM HAV titre was repeated which was found to be 38.73 (reactive), when compared to the initial titre of 8.35 (0-1.0).

So, the final diagnosis of juvenile polymyositis post viral hepatitis A was made. She was treated with oral prednisolone at 1 mg/kg dose along with methotrexate 10 mg once a week dose. She was symptomatically improved with treatment and was able to walk around without support.

Other treatment options available are Azathioprine, methotrexate, mycophenolate, cyclosporine as glucocorticoid sparing agents, IVIG if the patient has insufficient response to glucocorticoids and rituximab if the response to IVIG and glucocorticoids is insufficient.

Funding: No funding sources

Conflict of interest: None declared

Ethical approval: Not required

REFERENCES

1. Dalakas MC, Hohlfeld R. Polymyositis and dermatomyositis. *Lancet*. 2003;362(9388):971-82.
2. Nojima T, Hirakata M, Sato S, Fujii T, Suwa A, Mimori T, et al. A case of polymyositis associated with hepatitis B infection. *Clin Exp Rheumatol*. 2000;18(1):86-8.
3. Bohan A, Peter JB. Polymyositis and dermatomyositis. *N Engl J Med*. 1975;292(7):344-7.
4. Miller FW. Polymyositis, dermatomyositis. *Clinical Primer of Rheumatology*. Lippincott Williams and Wilkins; 2003:182-184.
5. Bohan A, Peter JB, Bowman RL, Pearson CM. A computer-assisted analysis of 153 patients with polymyositis and dermatomyositis. *Medicine*. 1977;56(4):255-86.

Cite this article as: Samuel HU, Jayachandran NV, Thulaseedharan NK. A case of juvenile polymyositis post viral hepatitis A. *Int J Adv Med* 2017;4:864-6.